Received: 13 April 2019 | Revised: 17 May 2019 | Accepted: 30 May 2019

DOI: 10.1111/jce.14018

ORIGINAL - EXPERIMENTAL

WILEY

Morphology of the Vieussens valve and its imaging in cardiac multislice computed tomography

Anna Żabówka MD[1] | Jakub Hołda[1] | Marcin Strona MD[2] | Mateusz Koziej MD, PhD[1] | Agata Krawczyk-Ożóg MD, PhD[1] | Katarzyna A. Jasińska[1] | Marcin Kuniewicz MD, PhD[3] | Jacek Lelakowski MD, PhD[3] | Mateusz K. Hołda MD, PhD[1]

[1]HEART—Heart Embryology and Anatomy Research Team, Department of Anatomy, Jagiellonian University Medical College, Cracow, Poland

[2]Department of Forensic Medicine, Jagiellonian University Medical College, Cracow, Poland

[3]Department of Electrocardiology, Institute of Cardiology, The John Paul II Hospital in Cracow, Jagiellonian University Medical College, Cracow, Poland

Correspondence
Mateusz K. Hołda, MD, PhD, HEART—Heart Embryology and Anatomy Research Team, Department of Anatomy, Jagiellonian University Medical College, Kopernika 12, 31-034 Cracow, Poland.
Email: mkh@onet.eu

Disclosures: None.

Abstract

Introduction: To deliver accurate morphological descriptions of the Vieussens valve (VV) and to investigate whether this structure could be visualized using standard contrast-enhanced electrocardiogram-gated multislice computed tomography (MSCT).

Methods: A total of 145 human autopsied hearts and 114 cardiac MSCT scans were examined.

Results: The VV was observed in both study groups, however, the detection rate was significantly worse in the MSCT examination (18.4% in MSCT vs 62.1% in cadavers, $P < .0001$). The VV height was larger in MSCT patients (2.8 ± 1.2 vs 5.4 ± 1.7 mm; $P < .0001$). No significant difference was found in the measured distance between the VV and the coronary sinus ostium between the two separate subgroups (27.3 ± 9.5 vs 24.4 ± 5.8 mm; $P = .18$). In autopsied material the most frequent valve location was the anterior wall of the coronary sinus (43.3%); the same was observed in MSCT scans (71.4%).

Conclusion: The VV is a common heart structure, present in over 60% of humans, located mainly on the anterior and superior circuit of the coronary sinus, with relatively high morphological variability. Large VVs, which pose a significant obstacle in catheterization procedures, may be visualized using standard-protocol contrast-enhanced cardiac MSCT.

KEYWORDS

catheterization, coronary sinus, great cardiac vein, MSCT

1 | INTRODUCTION

The coronary venous system, especially the coronary sinus, plays a significant role in many electrophysiological procedures, including resynchronization therapy, cardiac ablations, mitral valve repair, coronary blood flow studies, retrograde perfusion for thrombolysis, and cardioplegic solution.[1,2] Despite its clinical significance, the coronary venous system is characterized by high anatomic variability. Furthermore, some of its associated structures can significantly hinder catheterization procedures.[3,4] The presence of venous valves, especially the valve of the coronary sinus ostium (CSO) (Thebesian valve) and the valve of the great cardiac vein (Vieussens valve [VV]), along with tortuous veins and an unfavorable angulation of the tributaries of the coronary sinus remain the most important obstacles for trans-sinusoidal catheter procedures.[5,6]

The valve of the great cardiac vein, named after the 18th century French doctor and anatomist Raymond de Vieussens, is an important

anatomic landmark which separates the coronary sinus from the great cardiac vein.[7] Its presence, morphological features, and localization are of critical importance during coronary venous system cannulations, since the valve may hinder the procedure and cause serious complications.[4,8,9] Unfortunately, the literature surrounding VV morphology is limited. There is little information about how to perform in vivo imaging of this valve, and few resources discuss its anatomical features. This study seeks to address these two shortcomings. First, using cadaveric material, we sought to deliver accurate morphological descriptions of the VV. Second, we investigated whether this structure could be visualized using standard contrast-enhanced electrocardiogram-gated multislice computed tomography (MSCT). Finally, our study discussed the clinical implications associated with our findings.

2 | MATERIALS AND METHODS

This study was approved by the Bioethical Committee of the Jagiellonian University (1072.6120.120.2018). The study protocol conforms to the ethical guidelines of the 1975 Declaration of Helsinki.

2.1 | Study populations

The cadaveric part of the study was conducted at the Department of Anatomy of the Jagiellonian University Medical College in Cracow, Poland. A total of 145 human autopsied hearts was examined. Both sexes were included (27.6% female) and the age range of the subjects was between 18 and 94 years old (47.6 ± 18.1 years). The specimens were collected during routine medical autopsies due to incidental deaths at the Department of Forensic Medicine of the Jagiellonian University Medical College in Cracow, Poland. Five exclusion criteria were implemented. Subjects with: (a) severe cardiac anatomical defects, heart surgeries or heart grafts, (b) evident severe macroscopic pathologies of the heart or vascular system found during autopsy (aneurysms, storage diseases), (c) heart trauma, (d) a history of interventions within coronary venous system, and (e) macroscopic signs of cadaver decomposition were not included in the analysis.

In the imaging part of this study, 114 cardiac MSCT scans (28.1% female) of patients between the ages of 29 and 86 (62.6 ± 11.8 years) were analyzed. The analysis was specifically performed on patients who underwent a MSCT focused on the coronary venous system, before undergoing a coronary sinus cannulation procedure. The data were gathered at the Department of Electrocardiology at the Institute of Cardiology located at the John Paul II Hospital in Cracow, affiliated with the Jagiellonian University Medical College in Cracow. We excluded patients with the following conditions: (a) previous cardiac surgeries or coronary sinus interventions, (b) congenital heart defects, (c) poor imaging/scan quality, (d) presence of an implanted cardiac devices, and (e) presence of artifacts hindering coronary venous system visibility.

2.2 | Dissection and measurement of autopsied material

After dissection, all of the hearts were fixed in a 10% formalin solution. The specimens were preserved for a maximal period of 2 months before exact measurements were recorded. All 145 hearts were opened in a routine manner. This was done by creating an incision point between the orifice of the superior vena cava and the orifice of the inferior vena cava. The coronary sinus was gradually and carefully opened along its longitudinal axis via the posterior wall to allow for adequate observation. All descriptions and measurements were recorded according to the cardiac anatomical position. The first step in all dissections was to determine whether the VV was present. If found, a subjective assessment of its shape (flat vs concave), its location, and approximate number of valve leaflets were recorded. Moreover, the following measurements were made:

- the height of each leaflet of the VV (measured from the hinge line to the free edge of the leaflet),
- the distance between the VV (hinge line) and the CSO (VV–CSO),
- the distance between the oblique vein of the left atrium (OVLA) ostium and the CSO (OVLA–CSO),
- the distance between the OVLA ostium and the VV (hinge line) (OVLA–VV),
- the transverse diameter of the vessel at the junction point of the great cardiac vein/coronary sinus.

A calculation of the ratio between the height of the VV and the diameter of the coronary sinus was noted (VVh/CSd). All measurements were made using a 0.03 mm precision electronic caliper (YATO, YT–7201, Poland) and performed twice to reduce human error. The mean of the two measurements was rounded to the first decimal place.

2.3 | Cardiac computed tomography protocol

Before the cardiac MSCT examination procedure, every patient had their pulse checked. If the heart rate was over 70 beats per minute, the patient was administrated 10 or 40 mg of propranolol or 40 mg of verapamil, depending on the physician's recommendation. The examination was performed using a 64-row dual-source scanner (Siemens, Erlangen, Germany). The contrast-enhanced electrocardiogram-retrospectively gated image acquisitions were gathered during deep inspiration breath hold. The imaging parameters for dual-source computed tomography consisted of a tube voltage of 100 to 120 kV and an effective tube current of 350 to 400 mA. The collimation and temporal resolution were 2 × 32 × 0.6 mm and 165 ms, respectively. The time of arrival of the contrast agent to the ascending aorta was determined at the level of the carina. This was achieved with the test bolus method—first 15 mL of contrast agent was infused, which was followed by 20 mL of saline. The contrast agent was injected at a dose of 1.0 ml/kg at a rate of 5.5 mL/s followed by a 40 mL saline chaser with the same infusion rate. The acquisition delay was the

time of maximum density of the ascending aorta in the test bolus with an additional 6 seconds of delay. Images were reconstructed with a B26f and B46f kernel and an image matrix of 512 × 512 pixels. A multiphase reconstruction (from 10% to 100%) was done and 70% image reconstructions (mid-diastolic) were assessed. The post-processing and study evaluations were done with the use of multiplanar reconstructions.

2.4 | Computed tomography measurements

The first step was to assess whether the VV was present. Typically, the valve was visualized as a hypodense structure protruding from the vessel's wall into the lumen of the coronary sinus. Additionally, imaging of the valve often showed bilateral differences in contrast distribution. The shape (flat or concave), the location, and the number of leaflet valves leaflets were recorded. The exact same measurements as described in the cadaveric part of this study were performed. The height of the VV with respect to the diameter of the coronary sinus was also calculated (VVh/CSd). The measurements were performed using virtual calipers and were conducted by two different researchers. The reported results represent the average of the measured values rounded to the first decimal place.

2.5 | Statistical analysis

The data were reported as mean values with the corresponding standard deviations or determined percentages. Shapiro-Wilk tests were used to determine if the quantitative data were normally distributed. To verify a relative homogeneity of variance, we performed Levene's tests. We also performed the Student *t* tests and the Mann-Whitney U tests for statistical comparisons. Qualitative variables were compared using χ^2 tests of proportions for categorical variables. Correlation coefficients were calculated to establish any statistical dependence between parameters. Statistical analyses were performed using StatSoft STATISTICA 13.1 software for Windows (StatSoft Inc, Tulsa, OK). All *P*-values lower than .05 were considered statistically significant.

3 | RESULTS

3.1 | Cadaveric study

The VV was present in 62.1% (90 of 145) of the autopsied hearts examined (Figure 1). The majority of the valves (63.3%) had a concave shape, whereas the rest (36.7%, ie, 33 of 90) were flat. Besides their different shapes, the valves differed in their leaflet composition: single leaflet valves were observed in 72.2% of instances (65 of 90), two leaflet variants were present in 25.6% (23 of 90) of cases and three leaflet valves were found in 2.2% (2 of 90) of cases. Overall, the valves were classified into five distinct categories: single leaflet concave valves (46.7%), single leaflet flat valves (25.6%), double leaflet concave valves (16.7%), double leaflet flat valves (8.9%), and triple leaflet flat valves (2.2%). The most frequent valve location was the anterior wall of the coronary sinus (43.3%) and other common locations were the antero-superior wall (16.7%), the superior wall (15.6%), the inferior wall (11.1%), the posteroinferior wall (8.9%), and the anteroinferior wall (4.4%).

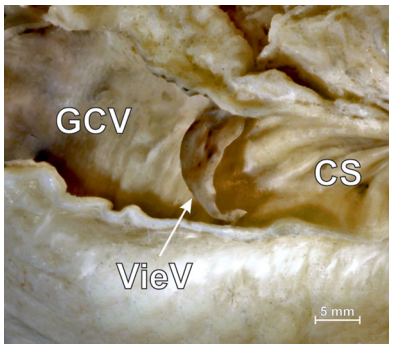

FIGURE 1 Photograph of cadaveric heart specimen showing a large Vieussens valves, (VieV) which covers the whole coronary sinus (CS) lumen. GCV, great cardiac vein

The average height of a single leaflet valve was 2.8 ± 1.2 mm (range, 0.5-8.5 mm). Valves with multiple leaflets had significantly smaller heights than their single leaflet valve counterparts (2.1 ± 1.2 mm for double leaflet valve and 1.7 ± 0.3 mm for triple leaflet valve, $P = .01$). There was no association between leaflet shape and height. The mean coronary sinus diameter was 7.4 ± 2.4 mm and the mean calculated VVh/CSd ratio was 0.24 (range, 0.05-0.90). The occlusive valve, defined as a valve covering ≥90% of the coronary sinus lumen, was present in 1.4% (2 of 145) of cases. The donor's age and body mass index had an association with leaflet height ($r = 0.34$, $P = .01$ and $r = 0.44$, $P = .02$, respectively), although no correlation was observed between leaflet height and cardiac weight.

The VV was located at a distance of 27.3 ± 9.5 mm (range, 7.5-55.2 mm) from the CSO (VV–CSO). In 46.9% (68 of 145) of all cases, the VV and the OVLA were detected conjointly. In 89.7% (61 of 68) of these specimens, the OVLA ostium was located between the CSO and the VV; the mean OVLA–VV distance was 4.1 ± 3.8 mm (range, 0.1-19.4 mm) and the mean OVLA–CSO distance was 26.8 ± 9.1 mm (range, 7.2-50.2 mm). In 10.3% (7 of 68) of these hearts, the left atrial oblique vein ostium was located distally from the VVs with a mean OVLA–VV distance of 6.9 ± 5.0 mm (range, 1.3-16.8 mm) and a mean OVLA–CSO distance of 26.9 ± 5.1 mm (range, 18.1-33.0 mm). The heart weight was positively correlated with the OVLA–CSO distance ($r = 0.38$, $P < .001$) and the VV–CSO distance ($r = 0.31$, $P = .002$). The donor's age also correlated with the OVLA–CSO distance ($r = 0.29$, $P = .01$).

3.2 | MSCT study

The VV was found in 18.4% (21 of 114) of all studied patients (Figure 2). The valves were predominantly concave (66.7%, 14 of 21), although some flat ones were detected as well (33.3%, 7 of 21). All of the identified valves were described as single leaflet valves. The most frequent valve location was the anterior wall of the coronary sinus (71.4%), although some valves were situated in the antero-superior wall (28.6%).

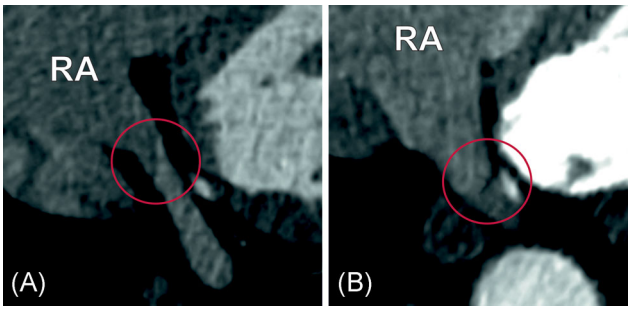

FIGURE 2 Vieussens valve visualized in MSCT. The hypodense structure protruding into the coronary sinus lumen is visible (A,B). Additionally, differences in the contrast distribution on both sides of the valve could be observed (A). MSCT, multislice computed tomography; RA, right atrium

The average VV leaflet height was 5.4 ± 1.7 mm (range, 2.3-8.7 mm). There was no association between leaflet shape and height. The mean coronary sinus diameter was 8.0 ± 2.9 mm and the mean calculated VVh/CSd ratio for MSCT patients was 0.72 (range, 0.34-0.97). The occlusive valve, defined as a valve covering ≥95% of the coronary sinus lumen, was present in 2.6% (3 of 114) of cases. The VV had a distance of 24.4 ± 5.8 mm (range, 9.6-34.7 mm) from the CSO (VV–CSO).

3.3 | Study comparison

The VV was observed in both study groups, however, the detection rate was significantly worse in the MSCT examination (18.4% valves detected in MSCT vs 62.1% in cadaveric findings, $P < .0001$). Moreover, all the valves identified during MSCT examination had a single leaflet, yet cadaveric findings recovered double and triple leaflet valves. The height of the VV differed between the two different visualization methods—higher measurements were reported in MSCT patients (2.8 ± 1.2 vs 5.4 ± 1.7 mm, $P < .0001$). This trend was also observed for the VVh/CSd ratio (0.24 vs 0.72, $P < .0001$). However, no significant difference was found in the measured distance between the VV and the CSO (VV–CSO) between the two separate subgroups (27.3 ± 9.5 vs 24.4 ± 5.8 mm, $P = .18$).

4 | DISCUSSION

Previous studies have estimated that the VV occurs on average in 78% of cases, but it can vary from 65% to 94% of the general population and some studies have provided details about its morphological features.[1,8,10-13] The current cadaveric examination demonstrated that the single leaflet-concave valve type (46.7%) is the most common subtype of VV. Most of the valves identified in this study were small, posing little risk of obstruction to the lumen of the coronary sinus. Nonetheless, a few large valves with thick leaflets were spotted, and these did significantly protrude into the vessel lumen (Figure 1).

Before performing a coronary sinus catheterization, it is crucial to know the location and morphological attributes of the VV, because serious complications may arise. According to Corcoran et al,[8] 80% of setbacks in catheter advancement within the coronary venous system are associated with the presence of a VV. Due to its specific shape and orientation within the coronary venous system, (a concave part directed towards the CSO) the valve can easily trap any introduced device. A bulging VV may significantly prolong various maneuvers, and it is sometimes the primary reason of a failed catheterization. It can also contribute to other serious complications such as vessel perforation and cardiac tamponade.[14,15]

Practically, the VV can serve as an important anatomic landmark for the identification of the OVLA (Marshall's vein) or its ligament.[9] These structures are particularly important for electrophysiologists due to their implication in the pathogenesis of atrial fibrillation.[16] Indeed, the OVLA ostium is a common target area for atrial ablations. Unfortunately, the co-occurrence of the VV with the aforementioned structures is not that prevalent. Our cadaveric study found that only 46.9% of cases had both structures. The ostium of the OVLA was predominantly located between the coronary ostium sinus and the VV hinge line (89.7% of cases) and it was often covered by the valve's leaflet. In this specific anatomical configuration, the VV could be used as a fulcrum for the catheter during Marshall's vein catheterization.

However, in other instances, the ostium of the OVLA was located far away from the VV, sometimes even behind this structure. Such location could also cause potential difficulties in vein cannulation procedures. Since our results shed light on the most frequent location of the VV, which can often be found on the anterior and superior circuit of the coronary sinus, we can use this knowledge to suggest that leaning the catheter against the posterior coronary sinus wall may help avoid a protruding VV. In rare cases where the valve is completely obstructive, clinicians can employ radiofrequency energy to traverse this obstacle.[5]

Despite its great clinical significance, the presence of the VV cannot usually be assessed preoperatively, because standard clinical resources seem to not allow the visualization of intravenous heart valves.[17] In our unique study, we aimed to determine if the MSCT could fill this void. During our analysis of cardiac contrast-enhanced computed tomographic scans, we identified structures that were likely VVs (Figure 2). Unsurprisingly, the rate of detection of these valves in the MSCT group was significantly lower than that in the cadaveric group. This can be explained by the mediocre capacity of a 64-row computed tomography scan to visualize small, thin structures.[18] The smallest leaflet valve detected by MSCT in our study had a height of 2.3 mm whereas the height of the smallest VV observed in cadaveric samples was of 0.5 mm. Results of this study show that MSCT might be a valuable tool for detecting large and hence clinically relevant VVs, helping gather substantial information necessary for a successful coronary venous system catheterization. Thus, a well performed MSCT screening has the potential to improve the operator's task before the intervention.[19] In the future, we hope that higher-resolution images and technological advancements will allow the detection of even more minute structures.[20]

This study is not without its limitations. First, the cadaveric part of the study was performed on formaldehyde-fixed postmortem specimens, which can be a source of minimal discrepancy when obtaining accurate

measurements. Second, the equipment we used for the MSCT part of this study was a 64-row scanner. Although this is the most commonly available diagnostic equipment in cardiologic centers across the globe, it is not the most accurate one. Technological advances and newer diagnostic equipment will most likely enable easier visualization of the VV in the future. Moreover, we need to acknowledge that some of the VVs identified via MSCT could have been artifacts erroneously recognized as valves. However, when we compared the localization of these hypodense structures with our cadaveric findings (VV–CSO distance), no significant differences were found. Finally, we cannot discuss the behavior and dimensional changes of the VV within the cardiac cycle. Functional heart studies are highly desirable to further explore these issues. We believe the above-mentioned limitations have little impact on the overall results and conclusions of this research.

5 | CONCLUSION

The VV is a common heart structure, present in over 60% of humans, located mainly on the anterior and superior circuit of the coronary sinus, with relatively high morphological variability. Large VVs, which pose a significant obstacle in catheterization procedures, may be visualized using standard-protocol contrast-enhanced cardiac MSCT.

ORCID

Mateusz K. Hołda http://orcid.org/0000-0001-5754-594X

REFERENCES

1. Zawadzki M, Pietrasik A, Pietrasik K, Marchel M, Ciszek B. Endoscopic study of the morphology of Vieussens valve. *Clin Anat*. 2004;17:318-321.
2. Randhawa A, Saini A, Aggarwal A, Rohit MK, Sahni D. Variance in coronary venous anatomy: a critical determinant in optimal candidate selection for cardiac resynchronization therapy. *Pacing Clin Electrophysiol*. 2013;36:94-102.
3. Mazur M, Żabówka A, Bolechała F, Kopacz P, Klimek-Piotrowska W, Hołda MK. Variations and angulation of the coronary sinus tributaries: Implications for left ventricular pacing. *Pacing Clin Electrophysiol PACE*. 2019;42(4):423-430.
4. Saremi F, Muresian H, Sánchez-Quintana D. Coronary veins: comprehensive CT-anatomic classification and review of variants and clinical implications. *Radiographics*. 2012;32:E1-E32.
5. Hołda MK, Klimek-Piotrowska W, Koziej M, Mazur M. Anatomical variations of the coronary sinus valve (Thebesian valve): implications for electrocardiological procedures. *Europace*. 2015;17:921-927.
6. Klimek-Piotrowska W, Hołda MK, Koziej M, Strona M. Anatomical barriers in the right atrium to the coronary sinus cannulation. *PeerJ*. 2016;3:e1548.
7. Loukas M, Clarke P, Tubbs RS, Kapos T. Raymond de Vieussens. *Anat Sci Int*. 2007;82:233-236.
8. Corcoran SJ, Lawrence C, McGuire MA. The valve of Vieussens: an important cause of difficulty in advancing catheters into the cardiac veins. *J Cardiovasc Electrophysiol*. 1999;10:804-808.
9. de Oliveira IM, Scanavacca MI, Correia AT, Sosa EA, Aiello VD. Anatomic relations of the Marshall vein: importance for catheterization of the coronary sinus in ablation procedures. *Europace*. 2007;9:915-919.
10. v. Lüdinghausen M, Ohmachi N, Boot C. Myocardial coverage of the coronary sinus and related veins. *Clin Anat*. 1992;5:1-15.
11. Duda B, Grzybiak M. About variability of Vieussen valve in the adult human heart. *Folia Morphol*. 2000;59:43-45.
12. Silver MA, Rowley NE. The functional anatomy of the human coronary sinus. *Am Heart J*. 1988;115:1080-1084.
13. Maros TN, Rácz L, Plugor S, Maros TG. Contributions to the morphology of the human coronary sinus. *Anat Anz*. 1983;154:133-144.
14. Strohmer B. Valve of Vieussens: an obstacle for left ventricular lead placement. *Can J Cardiol*. 2008;24:e63.
15. Hijazi ZM, Feldman T, Cheatham J, Sievert H. Complications during percutaneous interventions for congenital and structural heart disease. London: *Informa Healthcare*. 2009. 376 p.
16. Rodríguez-Mañero M, Schurmann P, Valderrábano M. Ligament and vein of Marshall: a therapeutic opportunity in atrial fibrillation. *Heart Rhythm*. 2016;13:593-601.
17. Młynarski R, Młynarska A, Gołba KS, Sosnowski M. Three-dimensional visualisation of coronary sinus ostium from the inside right atrium perspective. *Kardiol Pol*. 2018;76:536-541.
18. Nikolaou K, Flohr T, Knez A, et al. Advances in cardiac CT imaging: 64-slice scanner. *Int J Cardiovasc Imaging*. 2004;20:535-540.
19. Klimek-Piotrowska W, Koziej M, Hołda MK, Sałapa K, Kuniewicz M, Lelakowski J. The Thebesian valve height/coronary sinus ostium diameter ratio (H/D-Ratio) as a new indicator for specifying the morphological shape of the valve itself in multisliced computed tomography. *Int J Cardiol*. 2015;201:595-600.
20. Ghekiere O, Salgado R, Buls N, et al. Image quality in coronary CT angiography: challenges and technical solutions. *Br J Radiol*. 2017;90:20160567.

How to cite this article: Żabówka A, Hołda J, Strona M, et al. Morphology of the Vieussens valve and its imaging in cardiac multislice computed tomography. *J Cardiovasc Electrophysiol*. 2019;1-5. https://doi.org/10.1111/jce.14018