The Superficial Temporal Artery: Anatomical Map for Facial Reconstruction and Aesthetic Procedures

Aesthetic Surgery Journal
2018, 1–9

DOI: 10.1093/asj/sjy287
www.aestheticsurgeryjournal.com
OXFORD
UNIVERSITY PRESS

Mateusz Koziej, MD, PhD; Marek Trybus, MD, PhD; Mateusz Hołda, MD, PhD; Jakub Wnuk; Jakub Polak; Paweł Brzegowy, MD, PhD; Tadeusz Popiela, MD, PhD; Jerzy Walocha, MD, PhD; Krzysztof Tomaszewski, MD, PhD; and Anna Chrapusta, MD, PhD

Abstract

Background: The superficial temporal artery (STA), a terminal branch of the external carotid artery, supplies multiple regions of the scalp and face. Knowledge of the STA is important for reconstructive and aesthetic procedures of the head and face.

Objectives: The aim of this study was to map the STA in relation to anatomical landmarks.

Methods: Computed tomographic head angiographies of 215 patients were included in this study; the final analysis comprised 419 STAs. The STA's main branches and variants were identified. The diameters of the STA and its frontal and occipital branches were measured, and the distance between the STA tree and anatomical landmarks was delineated.

Results: Frontal and parietal branches were recorded in 98.1% and 90.7% of patients, respectively. The mean diameters, measured 1 and 7 cm from the STA bifurcation for the frontal branch, were 0.97 ± 0.32 and 0.81 ± 0.26 mm, respectively, and for the parietal branch, the diameters were 0.96 ± 0.28 and 0.76 ± 0.23 mm, respectively. The STA bifurcation point was located above the zygomatic arch (ZA) in 75.6%, below in 14.7%, and on the ZA in 9.7% of patients. The mean distance from the ZA center to the STA bifurcation was 16.8 ± 16.0 mm.

Conclusion: The STA artery and its main branches follow a conservative course, and serious anatomical variations are relatively rare. The STA and its main branches may be localized using simple anatomical landmarks. An anatomical map showing artery-free zones in the lateral forehead region was presented, which may prove useful for plastic, reconstructive, and aesthetic surgeons.

Level of Evidence: 4

Editorial Decision date: October 15, 2018; online publish-ahead-of-print October 23, 2018.

Dr Koziej is a Research Assistant, Department of Anatomy, Jagiellonian University Medical College; and Plastic Surgery Trainee, Malopolska Center for Burns and Plastic Surgery, The Ludwik Rydygier Hospital, Krakow, Poland. Dr Trybus is a Professor and Plastic Surgeon, Second Department of General Surgery, Jagiellonian University Medical College, Krakow, Poland. Dr Hołda is a Research Assistant, Dr Tomaszewski is an Associate Professor, and Dr Walocha is a Professor and Head of the Department of Anatomy, Jagiellonian University Medical College. Mr Wnuk and Mr Polak are Medical Students and Assistants, Dr Brzegowy is a Radiologist and an Assistant, Dr Popiela is a Professor, Radiologist and Head of the Department of Radiology, Department of Rescue Medicine and Multiorgan Trauma University Hospital, Krakow, Poland. Dr Chrapusta is an Associate Professor and Plastic Surgeon, Malopolska Center for Burns and Plastic Surgery, The Ludwik Rydygier Hospital, Krakow, Poland.

Corresponding Author:
Dr Marek Trybus, Second Department of General Surgery, Jagiellonian University Medical College, Kopernika 50, 31-501 Kraków, Poland.
E-mail: mt.ujcm@gmail.com

The superficial temporalis artery (STA), a terminal branch of the external carotid artery, arises in the parotid gland behind the neck of the mandible. It is divided into 2 main branches, the frontal and parietal. The artery supplies the skin and muscles located on the scalp and lateral side of the face, the parotid gland, and the temporomandibular joint.[1,2] In addition to the branches that mainly concern plastic surgery, the STA also branches into the transverse facial, auricular, zygomatico-orbital, and middle temporal arteries. Detailed knowledge of the anatomy of this region is essential for undertaking reconstructive and aesthetic procedures.

The temporal region borders the lateral part of the forehead, and these regions are supplied by the frontal branch of the STA. This region is of great aesthetic interest.[3,4] Because of its location neighboring the eyes, and because it often shows early signs of aging, it is one of the most common locations for dermal filler injections.[5,6] Proper injection technique and knowledge of the anatomy of this region, especially the location of the frontal branch of the STA, is crucial to avoid complications during injection, which include inflammatory nodules, tissue necrosis, hypersensitivity reaction, blindness, and cerebral ischemia.[7-9] Recent studies have emphasized the facial danger zones, and how to minimize the complications related to filler use.[10-12]

Another important clinical aspect of the STA supply is in reconstructive procedures that involve the temporoparietal, parieto-occipital, or the forehead and preauricular flaps.[13-18] These flaps are used to cover various head defects, including baldness and external ear reconstruction. Proper planning of reconstructive surgery is a basic step in obtaining a satisfactory effect, and is linked with achieving an appropriate blood supply to the flap. Thus, detailed knowledge of the location of the STA and its branches is important for such procedures. Computed tomographic angiography (CTA) is the first choice for preoperative imaging in facial reconstructive surgery, because its imaging of small vessels is superior to that of magnetic resonance angiography.[19]

A comprehensive knowledge of STA anatomy is crucial for avoiding serious complications and improving results. Thus, the aim of the present study was to present anatomical variations of the STA and develop a clinically useful map of the STA in relation to anatomical landmarks.

METHODS

The methods and protocols were performed in accordance with accepted guidelines. This study was approved by the Bioethical Committee of the Jagiellonian University, Krakow, Poland (no. 1072.6120.213.2017).

Study Group

Evaluation of STA anatomy in this retrospective cross-sectional study was conducted on patients who underwent a head CTA at the Department of Radiology, Department of Rescue Medicine and Multiorgan Trauma, University Hospital, Krakow, Poland between October 2017 and January 2018. Exclusion criteria were as follows: head trauma affecting the course of the artery, significant imaging artifacts (such as low quality or illegible images), history of craniectomy or craniotomy, and incomplete cross-sections. Of the initial 238 CTA patients available, 24 were excluded because of an insufficient field of view (n = 7), weak enhancement of the carotid artery (n = 6), repeated studies for 1 patient (n = 1), and missing data (n = 3). The remaining 215 patients were included in this study; 126 were females (58.6%) and 89 were males (41.4%). A total of 204 patients had their STA visualized bilaterally and 11 unilaterally, which provided a total of 419 STAs in the final analysis (right, 208; left, 211).

Computed Tomographic Angiography Method and Image Evaluation

The study was performed using a multi-row computed tomography scanner (GE Optima CT 660; GE Healthcare, Chicago, IL). The nonionic contrast agent iomeprol (70 mL administered; Iomeron 350; 350 mg iodine/mL; Bracco Imaging, Milan, Italy) was injected. After the bolus reached the common carotid artery at the level of C3-C4, the scanning procedure was started automatically. The imaged region ranged from the aortopulmonary window to the cranial vertex. The scanner settings were as follows: 120 kV, 200 mA, and 64 mm × 0.625 mm slice collimation. Axial 0.625-mm slices at increments of 1.25 mm were reconstructed using a 512 × 512 matrix, with a standard kernel applied.

The data were analyzed on a dedicated workstation (Advantage Workstation AW4.5; GE Healthcare, Chicago, IL) equipped with software for 3-dimensional volume-rendering postprocessing of images. All scans were reconstructed using a volume-rendering opacity setting of 45-300 Hounsfield unit and then investigated visually. The STA and its branches were included in the analysis, with data for both sides recorded separately. The features of the STA were evaluated by 4 radiologists who were experienced in head and neck evaluation.

Measurements

In each patient, the STA and its main branches were identified, and variants were noted. STA diameters were measured at the superior margin of the zygomatic arch (ZA), and

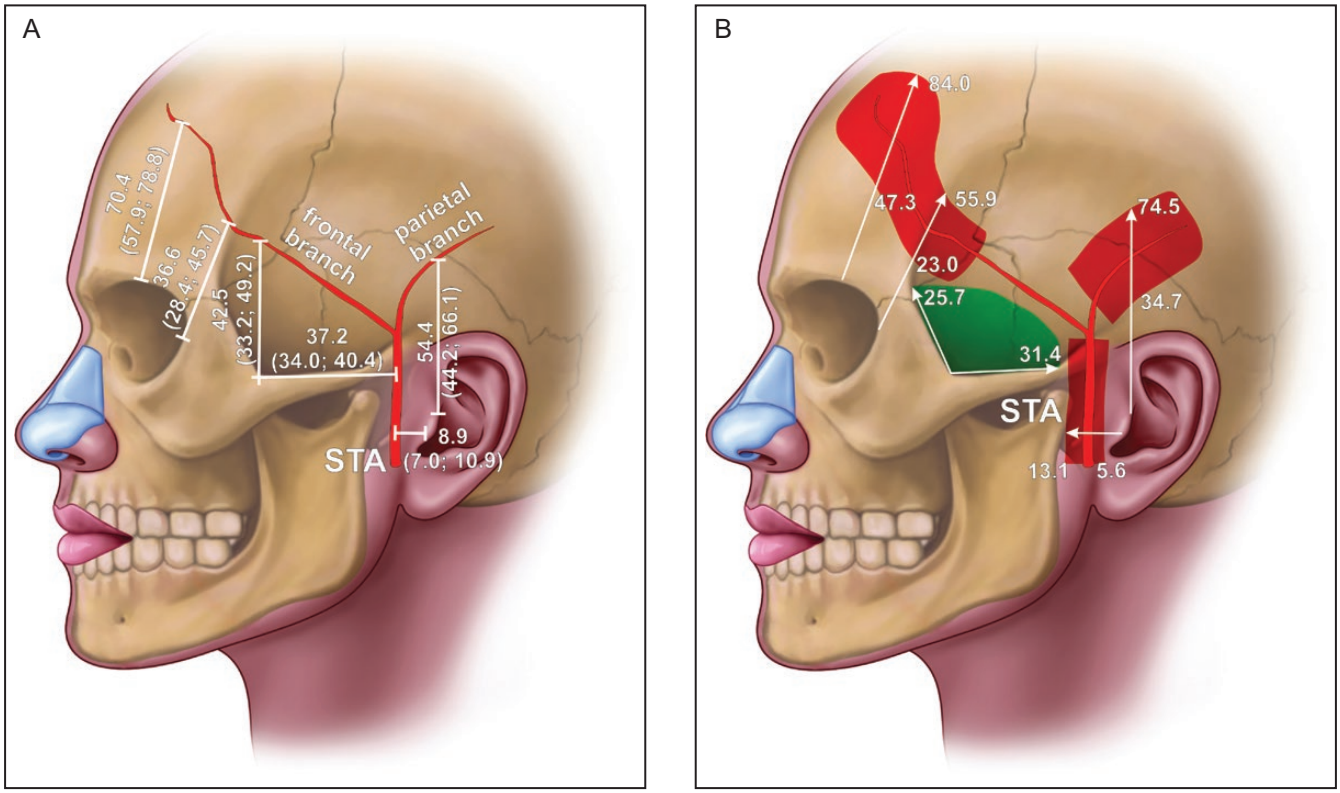

Figure 1. (A) Schematic view of the superficial temporal artery with main branches. Measured lines are shown as median values with lower and upper quartiles in millimeters. (B) Anatomical map of the forehead and the lateral head region. The superficial temporal artery–related zone (red) and artery-free zone (green) were delineated and estimated on 10th and 90th percentile values of measurement in millimeters.

1 cm before STA bifurcation. The diameters of the frontal and occipital branches were also noted 1 and 7 cm above the bifurcation. The bifurcation point was described in relation to the central point of the ZA (" + " above, and " − " below ZA). Two angles were also measured: (1) the angle between the frontal and parietal branches; and (2) the angle between the frontal branch and the ZA (Figure 1A). Moreover, 6 clinically important distances were delineated between the STA tree and anatomical landmarks, which are defined in Table 1 and marked in Figure 1A.

Statistical Analysis

Qualitative features were presented as frequencies and percentages. Normal distribution was assessed using the Shapiro-Wilk test. A P value of < 0.05 was considered to be statistically significant. The homogeneity of variance was confirmed with Levene's test. Quantitative features were characterized as mean ± standard deviation. Quantiles (Q1, median, Q3) were applied if a nonparametric test was performed to compare quantitative features in groups. To compare STA features between the left and right sides, a paired t test or the Wilcoxon rank test was used depending on whether data were normally distributed. Correlation coefficients were calculated to measure the statistical dependence between the parameters. The power analysis indicated that, to detect a simple correlation r ($r = 0.2$) using a 2-sided test, with a 5% significance level test ($\alpha = 0.05$), and 80% power ($\beta = 0.2$), the minimum sample size was 193. Statistical analyses were performed using Statistica version 13.1 (StatSoft Inc., Tulsa, OK).

RESULTS

The mean age of the included subjects was 53.9 ± 18.6 years (range, 18–92 years). The mean diameter of the STA measured 1 cm below the STA bifurcation was 1.6 ± 0.4 mm (range, 0.5–3.2 mm), and measured at the level of superior margin of the ZA, it was 1.3 ± 0.4 mm (measured for 331 STAs; range, 0.5–3.2 mm). There were no significant differences in the diameters between the left and right sides of the face ($P > 0.05$; Table 1).

Of the 419 visualized STAs, frontal branches were recorded in 411 patients (98.1%) and parietal branches in 380 sides/arteries (90.7%; Table 2, Figure 2A,B). The mean diameters measured 1 and 7 cm from the STA bifurcation were 0.97 ± 0.32 mm (range, 0.4–2.3 mm) and

Table 1. Location and Features of the Superficial Temporal Artery (STA) with Reference to Facial Structures

Parameter	Median (lower and upper quartiles)	10th percentile	90th percentile
The distance between the center of the supraorbital margin and the frontal branch, measured vertically	70.4 (57.9; 78.8)	47.3	84.0
The distance between the lateral angle of the orbital rim and the frontal branch, measured vertically	36.6 (28.4; 45.7)	23.0	55.9
The distance from the point of the corpus of zygomatic bone between the frontal and temporal processes to the frontal branch of the STA, measured vertically	42.5 (33.2; 49.2)	25.7	54.9
The shortest distance from the point of the corpus of the zygomatic bone between thefrontal and temporal processes to the point where the STA crossed thezygomatic arch	37.2 (34.0; 40.4)	31.4	43.5
The distance between the external auditory pore to the parietal branch of the STA, measured vertically	54.4 (44.2; 66.1)	34.7	74.5
The distance between the external auditory pore and the STA, measured horizontally	8.9 (7.0; 10.9)	5.6	13.1

Table 2. Mean Values ± Standard Deviations of the Diameters (mm) of the Superficial Temporal Artery (STA) and its Major Branches

		Right	Left	Total
STA	n	208	211	419
	diameter 1 cm below the STA bifurcation	1.4 ± 0.4	1.4 ± 0.4	1.4 ± 0.4
STA frontal branch	n (%)	204 (98.1)	207 (98.1)	411 (98.1)
	diameter 1 cm from the STA bifurcation	0.96 ± 0.32	0.98 ± 0.33	0.97 ± 0.32
	n (%) with diameter <1 mm, measured 1 cm from the STA bifurcation	88 (43.1)	78 (37.7)	166 (40.4)
	diameter 7 cm from the STA bifurcation	0.79 ± 0.25	0.84 ± 0.27	0.81 ± 0.26
STA parietal branch	n (%)	187 (89.9)	193 (91.5)	380 (90.7)
	diameter 1 cm from the STA bifurcation	0.96 ± 0.30	0.96 ± 0.27	0.96 ± 0.28
	n (%) with diameter <1 mm, measured 1 cm from the STA bifurcation	69 (36.9)	67 (34.7)	136 (35.8)
	diameter 7 cm from the STA bifurcation	0.78 ± 0.24	0.79 ± 0.23	0.76 ± 0.23

No statistically significant differences were found between right and left sides ($P > 0.05$).

0.81 ± 0.26 mm (range, 0.3–2.4 mm), respectively, for the frontal branch, and 0.96 ± 0.28 mm (range, 0.4–2.6 mm) and 0.76 ± 0.23 mm (range, 0.3–2.2 mm), respectively, for the parietal branch. Arteries with an inner diameter less than 1 mm (measured 1 cm from the STA bifurcation) were observed in 166 STAs (40.4%) for the frontal branch and in 136 STAs (35.8%) for the parietal branch.

The bifurcation point of the STA was located above the ZA in 282 STAs (75.6%), below the arch in 55 STAs (14.7%), and was projected onto the ZA in 36 STAs (9.7%; Figure 3). The mean distance from the center of the ZA to the STA bifurcation was 23.8 ± 11.4 mm (range, 2.6–65.3 mm) for a bifurcation located above the arch and −8.1 ± 4.4 mm (range, −23.4 to −2.3 mm) for a bifurcation located below the ZA. The location of the bifurcation point is strongly correlated with the location of the frontal branch, but not with the parietal branch; for high-branching STAs, the frontal branch is located significantly higher in relation to the lateral angle of the orbital rim ($r = 0.44$, $P < 0.001$) and the zygomatic bone ($r = 0.48$, $P < 0.001$).

The angle between the frontal and parietal branches was 67.5 ± 24.9° (range, 5.0° − 161.3°), and the angle between the frontal branch and the ZA was 43.2 ± 12.2° (range, 6.5° − 110.8°). The angle between the frontal and parietal branches was strongly correlated with the location of the STA bifurcation point and was greater for high-branching arteries ($r = 0.69$, $P < 0.001$). An anastomosis between the parietal and frontal branches was noted in 15 STAs (3.6%) and the mean distance measured along the frontal branch from the STA bifurcation to the anastomosis point was 91.1 ± 24.1 mm (range, 52.3–132.3 mm; Figure 2C). In 3 cases, a double parietal branch was noted (Figure 2D), and in 2 patients, it branched off the occipital artery. In 16 patients, the parietal branch was hypotrophic or absent and its course was replaced by a hypertrophic posterior auricular artery (Figure 2E-F).

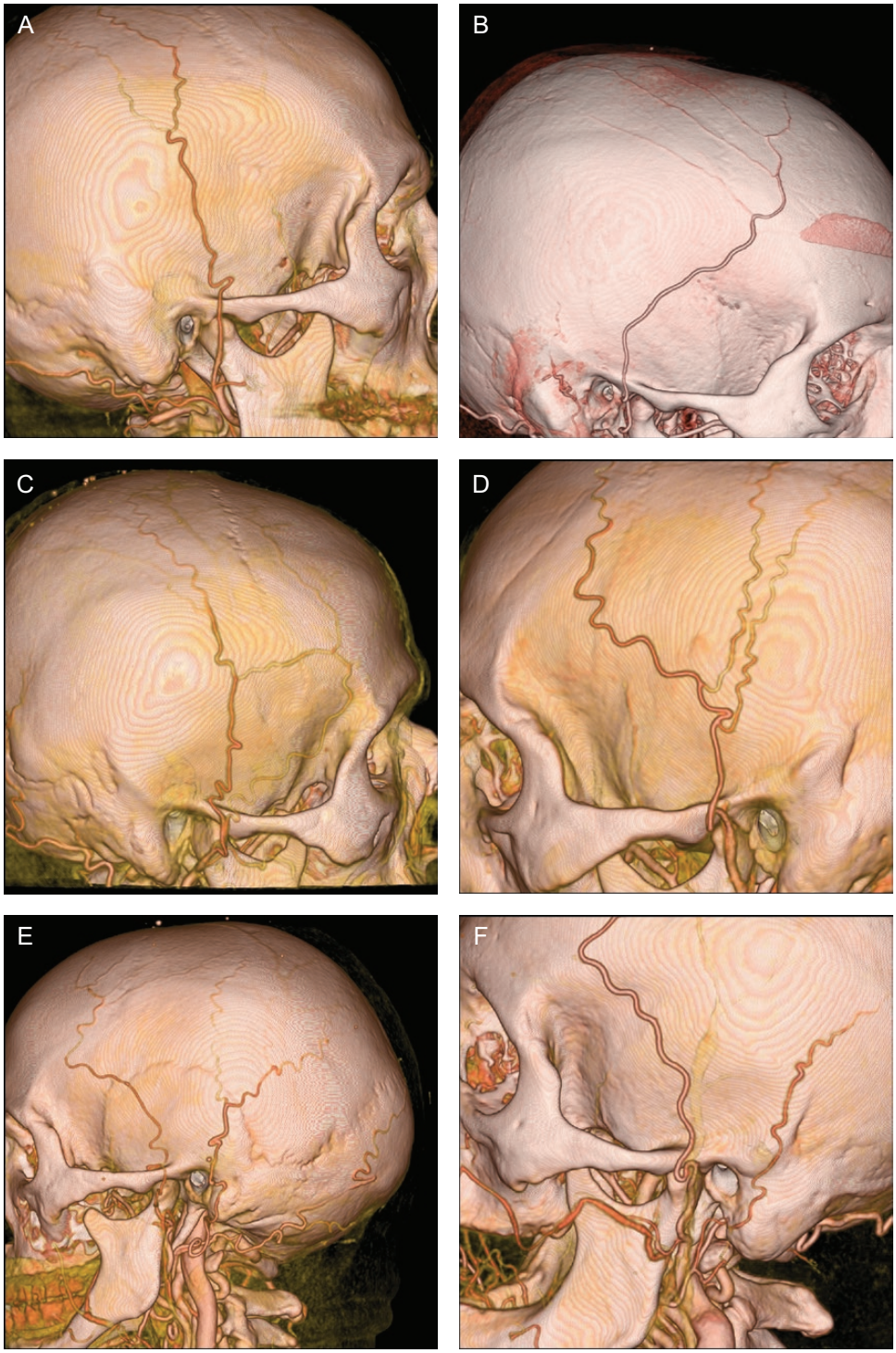

Figure 2. Computed tomographic angiography 3-dimensional reconstructions showing variants of the superficial temporal artery tree: (A) absence of the frontal branch; (B) absence of the parietal branch; (C) anastomosis between the frontal and parietal branch; (D) doubled parietal branch; (E) parietal branch branches off the hypertrophic auricular posterior artery; and (F) absence of the parietal branch and hypertrophy of the auricular posterior artery.

Table 1 and Figure 1 show the morphometric relationship between the STA tree and the facial anatomical landmarks. Using the 10th and 90th percentiles for distances between the anatomical landmarks and STA components, artery-free and arterial zones were delineated in the studied area of the face and scalp. In the preauricular area, the

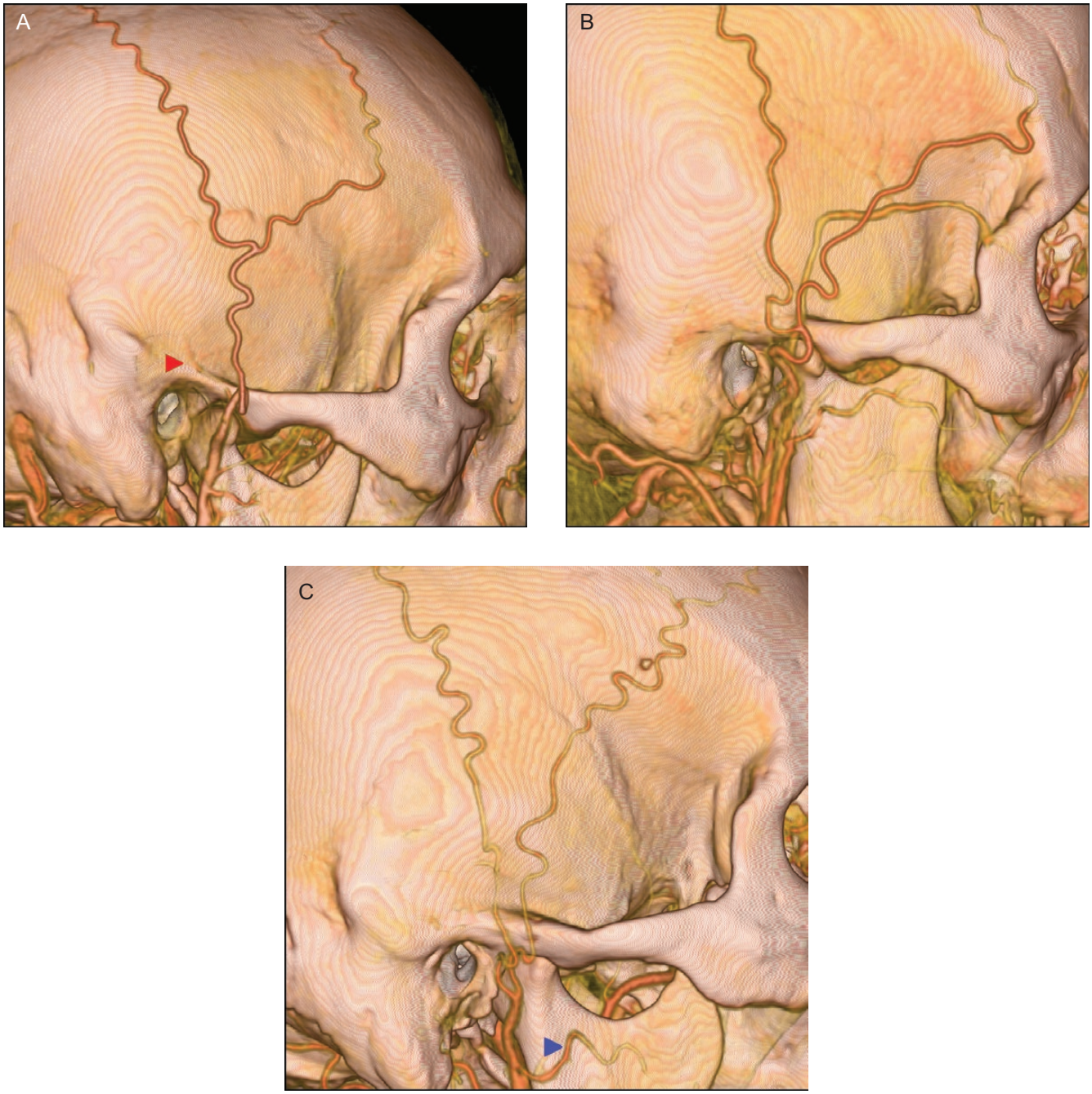

Figure 3. Computed tomographic angiography 3-dimensional reconstructions showing the location of the superficial temporal artery bifurcation point in relation to the zygomatic arch: (A) above, (B) over, and (C) below. The red arrowhead indicates the beginning part of the middle temporal artery in its groove, and the blue arrowhead indicates the transverse facial artery.

safe zone, defined as an artery-free zone, is estimated to be only 5.6 mm wide, and the STA artery should be expected to be 5.6 to 13.1 mm from the external auditory pore (arterial zone; Figure 1B). The location of the STA parietal branch could be also estimated based on its relationship to the external auditory pore, but the zone where the parietal branch is located is much wider (39.8 mm) and extends from 34.7 to 74.5 mm above the pore (Figure 1B). The location of the parietal branch in this area does not depend on the location of the STA bifurcation point ($r = 0.12$, $P < 0.001$).

The frontal branch of the STA and skull bone structures form a triangle or trapezius in the area of the temporal hollow, and the zygomatic bone may be used as an orientation point (Figure 1B). The safe zone extends 25.7 mm above and 31.4 mm towards the ear from the zygomatic

bone. The 30-mm-wide arterial zone extends from 25 to 55 mm above the zygomatic bone (Figure 1B). Another wide arterial zone (about 35 mm) related to the frontal branch may be located on the forehead, above the supraorbital margin (Figure 1B). The artery-free zone on the forehead extends to 23.0 mm above the lateral angle of the orbital rim and to 47.3 mm above the central part of the supraorbital margin (Figure 1B). Multidimensional analysis shows that the course of the frontal branch is more conservative in its final segment, but its initial route (up to the lateral angle of the orbital rim) strongly depends on the location of the STA bifurcation.

DISCUSSION

Several, mainly small, anatomical studies have described the STA.[10,18,20-25] The current study presents the variations and morphometric features of the STA tree and delivers a morphological map delineating the area where the STA, together with its main branches, may be found in most patients.

There are several situations in which it is necessary to precisely locate arteries in the lateral forehead area, either to find and use the vessel or to avoid its injury. The STA's adequate diameter, predictable location, and accessibility make this vessel ideal for free flap reconstruction of the midface and scalp.[26,27] The STA and its branches are also important in reconstruction procedures that require creation of a temporalis flap. This flap is mainly used for reconstruction of maxilla, mandible, and oropharynx defects,[14] as well as to create a temporoparietal fascia flap, which can be used in various procedures such as both cutaneous and mucosal oncologic defects; reconstruction of the auricle, skull base, and orbit; hair-bearing tissue transfer; and facial augmentation.[28-30] The successful use of these flaps depends upon the anatomical features of the pedicles that contain frontal or parietal branches.[18] Because of advances in microsurgery, free tissue transfer has become the preference for many surgeons in craniofacial reconstruction. Several other indications for temporalis flap use have been noted, including anophthalmia, unilateral maxillectomy defects, and facial reanimation in selected cases of facial nerve palsy.[14] However, biopsy of the frontal STA branch is considered to be the gold standard method for investigating giant-cell arteritis, where there is a risk of iatrogenic injury of the temporal branch of the facial nerve.[31] Thus, an appropriate anatomical approach to the biopsy is necessary to decrease the risk of complications.

The STA runs perpendicular to the tragus in the preauricular area, and should be expected in the area extending from 5.6 to 13.1 mm anterior to the external auditory pore (Table 1, Figure 1B). Other anatomical structures that may be found in this area are the temporal and zygomatic branches of the facial nerve, 1 or 2 accompanying veins, and the auriculotemporal nerve. The STA can be noninvasively located using light palpation or color duplex sonography examination at the preprocedural stage.[32,33] However, when performing aesthetic procedures, imaging techniques may not be available and basic knowledge of the STA location is crucial. One of the general principles for safe filler injections is to "be aware of the pertinent anatomy outlined in the danger zones."[11] Even when a practitioner is unable to find a vessel in a particular patient, this basic anatomical knowledge can minimize potential risk of complications and help predict potential adverse events.

The current study confirmed that the STA bifurcation point is usually located above the ZA.[18,25,34] There is a purely academic dispute as to which branch of the STA should be considered a direct extension of this artery. In our study, the frontal branch was observed to be a direct extension of the STA slightly more often than the parietal branch. However, no differences in these vessels' dimensions were found in the current study, which is in contrast to previous anatomical studies that highlighted the dominance of the frontal branch.[18] Therefore, based on our results, we conclude that both STA branches should be considered equivalent.

Our results show that the STA frontal branch is more uniform than the parietal branch in its origin, but its course is more variable. The frontal branch is rarely encountered below the ZA, and its position on the forehead is strongly correlated with the location of the STA bifurcation point. Within the temporal region, the frontal branch can be found on the bone point located between frontal and temporal processes of the zygomatic bone. The artery-free zone may be estimated as a section of a circle with a center in this point and a radius of 3 cm (Figure 1B). This would be a reasonable area to use for filler injection to minimize potential artery damage or occlusion. However, it is necessary to remember to stay above the temporoparietal fascia so as not to inject filler into the middle temporal vessels. To avoid direct injury to the frontal branch, Sheuer et al[12] suggested performing soft-tissue filler injections of the temporal region from lateral to medial in the superficial subcutaneous plane just below the dermis to maximize safety. Because the course of the artery in this region above the artery-free zone is wide (3 cm), we advise that the needle should be in constant motion in this region to prevent accidental puncture.

Just above the supraorbital margin, the wide artery-free zone extends up to 47 mm above the eyebrow. Unfortunately, a recent study by Shin et al[31] showed that this region overlaps with a neural danger zone, where the temporal branch of the facial nerve is located. However, although the courses of the artery and nerve are parallel, the nerve terminates earlier than the STA branch, and has a smaller diameter and a dispersed

fiber arrangement. This vicinity creates the possibility of mutual damage to structures, and may be clinically used to localize the temporal branch of the facial nerve during rhytidectomy. Lei et al[35] suggested in their study that a 5- to 6-cm temporal incision in the hairline made approximately 1 to 2 cm superior to the frontal branch is likely safe during rhytidectomy. The STA can be used to locate the temporal branch of the facial nerve. In the temporal region this nerve is situated inferior and anterior to the STA frontal branch. Shin et al[31] outlined 2 useful distances that can help locate the facial nerve. The first one is a horizontal line passing through the lateral cantus and the root of the helix, and the second is a parallel line passing through the supraorbital margin. The mean distances between the STA frontal branch and the temporal branch of the facial nerve are estimated to be 17.7 ± 7.3 and 23.2 ± 9.9 mm, respectively.[31]

As much as 40% of the frontal and 36% of the parietal STA branches are almost negligibly small (< 1 mm in diameter) and their damage during aesthetic procedures, especially injections, is unlikely. Our study also shows another important variant: the anastomosis between the parietal and frontal branches, which is present in 3.6% of patients. Such an anastomosis is located high on the skull and its presence should be considered when performing procedures in this region (Figure 2C).

Although this study is the largest to date on STA anatomy, it has several limitations. First, the STA tree is composed of smaller vessels that may not have been detected by CTA because this imaging method lacks sufficient resolution. Second, the depth at which arteries run (relative to the skin surface) was not assessed. Regarding the STA location within the temporal region tissue layers, previous studies have shown that above the ZA, the STA is located within the temporoparietal fascia (superficial temporal fascia). The major branches of the STA never reach the deep temporal fascia, although they supply the subdermal layer.[36] Third, all the analyzed patients were Caucasian; thus, no interracial differences were investigated. Fourth, only the internal diameters of the arteries were measured, which is the result of the visualization tool used and may be explain why our diameters are smaller than those reported in cadaveric studies.[18,25,37] Moreover, the anatomy of veins, which usually accompany arteries and are also important vessels in reconstructive and aesthetic medicine, was not evaluated in this study. Finally, the proposed anatomical map should not be used as a universal tool, because variations may occur in individual patients. Specifically, patients with craniofacial deformities were not included and the above results cannot be extrapolated to this group.

CONCLUSIONS

The STA and its main branches follow a conservative course, and significant anatomical variations are relatively rare. The frontal branch is negligibly small (< 1 mm in diameter) in 40% of patients; the same is observed for the parietal branch in 36% of patients. The STA and its main branches may be located through the use of simple anatomical landmarks. An anatomical map showing artery-free zones, which may assist plastic, reconstructive, and aesthetic surgeons in planning procedures in the lateral forehead region, was presented.

Disclosures

The authors declared no potential conflicts of interest with respect to the research, authorship, and publication of this article.

Funding

The authors received no financial support for the research, authorship, and publication of this article.

REFERENCES

1. Standring S, Neil B, Gray H. *Gray's Anatomy : The Anatomical Basis of Clinical Practice*. Edinburgh: Churchill Livingstone/Elsevier; 2008.
2. Whetzel TP, Mathes SJ. Arterial anatomy of the face: an analysis of vascular territories and perforating cutaneous vessels. *Plast Reconstr Surg.* 1992;89(4):591-603; discussion 604.
3. Huang RL, Xie Y, Wang W, et al. Anatomical study of temporal fat compartments and its clinical application for temporal fat grafting. *Aesthet Surg J.* 2017;37(8):855-862.
4. Pessa JE, Kenkel JM, Heldermon CD. Periorbital and temporal anatomy, "targeted fat grafting," and how a novel circulatory system in human peripheral nerves and brain may help avoid nerve injury and blindness during routine facial augmentation. *Aesthet Surg J.* 2017;37(8):969-973.
5. Lambros V. A technique for filling the temples with highly diluted hyaluronic acid: the "dilution solution". *Aesthet Surg J.* 2011;31(1):89-94.
6. Cotofana S, Mian A, Sykes JM, et al. An update on the anatomy of the forehead compartments. *Plast Reconstr Surg.* 2017;139(4):864e-872e.
7. Sorensen EP, Urman C. Cosmetic complications: rare and serious events following botulinum toxin and soft tissue filler administration. *J Drugs Dermatol.* 2015;14(5):486-491.
8. Ozturk CN, Li Y, Tung R, Parker L, Piliang MP, Zins JE. Complications following injection of soft-tissue fillers. *Aesthet Surg J.* 2013;33(6):862-877.
9. DeLorenzi C. Complications of injectable fillers, part 2: vascular complications. *Aesthet Surg J.* 2014;34(4):584-600.
10. Lee JG, Yang HM, Hu KS, et al. Frontal branch of the superficial temporal artery: anatomical study and clinical

implications regarding injectable treatments. *Surg Radiol Anat.* 2015;37(1):61-68.
11. Scheuer JF, Sieber DA, Pezeshk RA, Campbell CF, Gassman AA, Rohrich RJ. Anatomy of the facial danger zones. *Plast Reconstr Surg.* 2017;139(1):50e-58e.
12. Scheuer JF 3rd, Sieber DA, Pezeshk RA, Gassman AA, Campbell CF, Rohrich RJ. Facial danger zones: techniques to maximize safety during soft-tissue filler injections. *Plast Reconstr Surg.* 2017;139(5):1103-1108.
13. Juri J. Use of parieto-occipital flaps in the surgical treatment of baldness. *Plast Reconstr Surg.* 1975;55(4):456-460.
14. Spanio Di Spilimbergo S, Nordera P, Mardini S, et al. Pedicled temporalis muscle flap for craniofacial reconstruction: a 35-year clinical experience with 366 flaps. *Plast Reconstr Surg.* 2017;139(2):468e-476e.
15. Sugio Y, Kubo T, Seike S, Hosokawa K. Divided and sliding superficial temporal artery flap for primary donor-site closure. *Plast Reconstr Surg Glob Open.* 2016;4(11):e1115.
16. Wang Y, Long X, Wang X. Reconstruction of periorbital soft tissue defect with reversed superficial temporal artery island flap. *Ann Plast Surg.* 2014;73(Suppl 1):S70-S73.
17. Yamauchi M, Yotsuyanagi T, Yamashita K, Ikeda K, Urushidate S, Mikami M. The reverse superficial temporal artery flap from the preauricular region, for the small facial defects. *J Plast Reconstr Aesthet Surg.* 2012;65(2):149-155.
18. Pinar YA, Govsa F. Anatomy of the superficial temporal artery and its branches: its importance for surgery. *Surg Radiol Anat.* 2006;28(3):248-253.
19. Soga S, Pomahac B, Mitsouras D, et al. Preoperative vascular mapping for facial allotransplantation: four-dimensional computed tomographic angiography versus magnetic resonance angiography. *Plast Reconstr Surg.* 2011;128(4):883-891.
20. Medved F, Manoli T, Medesan R, et al. In vivo analysis of the vascular pattern of the superficial temporal artery based on digital subtraction angiography. *Microsurgery.* 2015;35(5):380-386.
21. Manoli T, Medesan R, Held M, et al. Bilateral comparison of the vascular pattern of the superficial temporal artery based on digital subtraction angiography. *Surg Radiol Anat.* 2016;38(2):179-186.
22. Imanishi N, Nakajima H, Minabe T, Chang H, Aiso S. Venous drainage architecture of the temporal and parietal regions: anatomy of the superficial temporal artery and vein. *Plast Reconstr Surg.* 2002;109(7):2197-2203.
23. Cobb MI, Galvin L, Gonzalez LF. Superficial temporal artery: the "C" shape half-buttonhole configuration as it courses over the zygomatic arch. *Surg Radiol Anat.* 2016;38(4):493-495.
24. Chen TH, Chen CH, Shyu JF, Wu CW, Lui WY, Liu JC. Distribution of the superficial temporal artery in the Chinese adult. *Plast Reconstr Surg.* 1999;104(5):1276-1279.
25. Tayfur V, Edizer M, Magden O. Anatomic bases of superficial temporal artery and temporal branch of facial nerve. *J Craniofac Surg.* 2010;21(6):1945-1947.
26. Hansen SL, Foster RD, Dosanjh AS, Mathes SJ, Hoffman WY, Leon P. Superficial temporal artery and vein as recipient vessels for facial and scalp microsurgical reconstruction. *Plast Reconstr Surg.* 2007;120(7):1879-1884.
27. Halvorson EG, Cordeiro PG, Disa JJ, Wallin EF, Mehrara BJ. Superficial temporal recipient vessels in microvascular orbit and scalp reconstruction of oncologic defects. *J Reconstr Microsurg.* 2009;25(6):383-387.
28. Brent B, Upton J, Acland RD, et al. Experience with the temporoparietal fascial free flap. *Plast Reconstr Surg.* 1985;76(2):177-188.
29. Collar RM, Zopf D, Brown D, Fung K, Kim J. The versatility of the temporoparietal fascia flap in head and neck reconstruction. *J Plast Reconstr Aesthet Surg.* 2012;65(2):141-148.
30. Chrapusta A, Koziej M, Bonczar T. Examples of clinical use of the superficial temporal artery. *Plast Surg Burn.* 2017;5(4):165-173.
31. Shin KJ, Shin HJ, Lee SH, Koh KS, Song WC. Surgical anatomy of the superficial temporal artery to prevent facial nerve injury during arterial biopsy. *Clin Anat.* 2018;31(4):608-613.
32. Chang KP, Lai CS, Tsai CC, Lin TM, Lin SD. Total upper lip reconstruction with a free temporal scalp flap: long-term follow-up. *Head Neck.* 2003;25(7):602-605.
33. Karahaliou M, Vaiopoulos G, Papaspyrou S, Kanakis MA, Revenas K, Sfikakis PP. Colour duplex sonography of temporal arteries before decision for biopsy: a prospective study in 55 patients with suspected giant cell arteritis. *Arthritis Res Ther.* 2006;8(4):R116.
34. Kim BS, Jung YJ, Chang CH, Choi BY. The anatomy of the superficial temporal artery in adult koreans using 3-dimensional computed tomographic angiogram: clinical research. *J Cerebrovasc Endovasc Neurosurg.* 2013;15(3):145-151.
35. Lei T, Xu DC, Gao JH, et al. Using the frontal branch of the superficial temporal artery as a landmark for locating the course of the temporal branch of the facial nerve during rhytidectomy: an anatomical study. *Plast Reconstr Surg.* 2005;116(2):623-629; discussion 630.
36. Abul-Hassan HS, von Drasek Ascher G, Acland RD. Surgical anatomy and blood supply of the fascial layers of the temporal region. *Plast Reconstr Surg.* 1986;77(1):17-28.
37. Stock AL, Collins HP, Davidson TM. Anatomy of the superficial temporal artery. *Head Neck Surg.* 1980;2(6):466-469.