Europace (2017) **0**, 1–6
doi:10.1093/europace/euw423

BASIC SCIENCE

Spatial relationship of blood vessels within the mitral isthmus line

Mateusz K. Hołda[1,2]*, Mateusz Koziej[1,2], Jakub Hołda[1,2], Kamil Tyrak[1,2], Katarzyna Piątek[1,2], Agata Krawczyk-Ożóg[3], and Wiesława Klimek-Piotrowska[1,2]

[1]Department of Anatomy, Jagiellonian University Medical College, Cracow, Kopernika 12, 31-034 Krakow, Poland; [2]HEART—Heart Embryology and Anatomy Research Team, Jagiellonian University Medical College, Cracow, Kopernika 12, 31-034 Krakow, Poland; and [3]2nd Department of Cardiology and Cardiovascular Interventions, University Hospital, Kopernika 19, 31-501 Krakow, Poland

Received 5 October 2016; editorial decision 29 November 2016; accepted 1 December 2016

Aims The aim of this study was to assess the spatial relationship of blood vessels and the thickness of the atrial wall within the mitral isthmus line.

Methods and results A total of 200 randomly selected autopsied adult human hearts (Caucasian) were examined. The mitral isthmus line was cut longitudinally and the thickness of the left atrial wall was measured. The blood vessels within the isthmus were identified and their relationship with the endocardial surface (ES), mitral annulus (MA), and the left inferior pulmonary vein (LIPV) ostium was assessed. The mean myocardial thickness in the upper, middle, and lower 1/3 of the mitral isthmus section were 1.9 ± 1.0, 3.0 ± 1.5, and 2.7 ± 1.3 mm, respectively. The great cardiac vein (GCV) was present within the isthmus in 98.0%, the left circumflex artery (LCx) in 57.0%, and the Marshall vein in 35.0% of all hearts. The GCV was located 4.5 ± 2.2 mm from the ES, 7.3 ± 5.3 mm from the MA, and 24.3 ± 7.3 mm from the LIPV. The LCx was situated 3.8 ± 2.3 mm from the ES, 7.9 ± 5.1 mm from the MA, and 25.3 ± 8.0 mm from the LIPV. We were able to detect eight different patterns of GCV and LCx mutual arrangement within the mitral isthmus line.

Conclusion The myocardium is the thinnest in the upper 1/3 sector, and the blood vessels are mainly located in the middle and lower 1/3. In 49.1%, the LCx is situated at a distance of less than 3 mm from the ES. In 55.3%, the LCx is located between the GCV and ES of the left atrium.

Keywords Atrial fibrillation • Left atrial isthmus • Lateral isthmus • Great cardiac vein • Coronary sinus • Left circumflex coronary artery

Introduction

The mitral isthmus (or left atrial isthmus) is a part of the postero-inferior area of the lateral left atrial wall, located between the left inferior pulmonary vein (LIPV) ostium and the mitral valve annulus (MA).[1] Clinically it is used as a site for linear ablation in peri-mitral flutter and as an adjuvant line to pulmonary vein isolation during radiofrequency catheter ablation for atrial fibrillation.[2] Transmural lesions in the mitral isthmus may interrupt the conduction pathways and macro-reentrant circuits and be beneficial in patients with left atrial arrhythmias. Unfortunately, mitral isthmus linear ablation is challenging and the complete bidirectional conduction block between the LIPV and the lateral (MA) often may not be achieved and if this fails may be pro-arrhythmogenic.[3,4]

Some anatomical features of this region significantly impede the use of ablation. One of them is that the mitral isthmus line may transect two relatively large blood vessels running in the epicardial aspect: the left circumflex coronary artery (LCx) and the great cardiac vein (GCV) or coronary sinus (CS).[5] The proximity of these arteries and veins may affect this procedure. The blood flow inside the GCV/CS and LCx may act as a heat-sink and be responsible for local cooling of the atrial myocardium, thus reducing the efficacy of mitral isthmus

* Corresponding author. Tel: +0048 12 422 95 11; fax: +0048 12 422 95 11. *E-mail address*: mkh@onet.eu

What's new?

- In 7.5% of hearts, the significant segmental narrowing (below 0.8 mm) of the atrial wall in the middle sector of the mitral isthmus may be found.
- The great cardiac vein (GCV) is present within the mitral isthmus section in 98.0%, while the left circumflex artery only in 57.0% of cases.
- In 16.7%, the left circumflex artery is located closer than 2 mm from the endocardial surface and in 49.1% closer than 3 mm.
- In 55.3%, the left circumflex artery, when present, is located between the GCV and endocardial surface of the left atrium.
- Eight different patterns of GCV and left circumflex artery mutual arrangement within the mitral isthmus line may be detected.

ablation.[6] Moreover, the radiofrequency energy application may lead to thrombosis inside the vessels, be a cause of acute spasm, or even damage the blood vessels' walls.[7,8]

The aim of this study was to assess the spatial relationship of blood vessels and the thickness of the myocardium within the mitral isthmus line to gain a deeper understanding. This may help to increase efficiency and avoid serious complications during mitral isthmus ablation and other surgical and minimally invasive procedures within this area.

Methods

Study population

Our study included 200 randomly selected adult human hearts (Caucasian) of both sexes (23.5% females) aged from 17 to 94 (mean = 47.5 ± 17.7) years. The average measured body mass index of the individuals was 26.8 ± 4.4 kg/m^2, and the average body surface area was 1.9 ± 0.2 m^2. The hearts were collected during routine forensic medical autopsies. The primary causes of death included suicide, murders, traffic accidents, and home accidents. The exclusion criteria included severe anatomical defects, heart trauma, heart grafts, evident severe macroscopic pathologies of the heart, or vascular system found during autopsy and macroscopic signs of cadaver decomposition. No cases of death due to heart failure were observed. There were no cases with a medical history of any type of arrhythmia. This study was approved by the Bioethical Committee of Jagiellonian University Medical College, Cracow, Poland. The study protocol conforms to the ethical guidelines of the 1975 Declaration of Helsinki.

Dissection and measurements

The hearts were dissected together with the proximal portions of the great vessels: the ascending aorta, pulmonary trunk, superior and inferior vena cava, and all of the pulmonary veins. We weighed the hearts before fixation using a 0.5 g precision electronic laboratory scale. After dissection, all of the hearts were fixed by immersion in 10% paraformaldehyde solution for a maximum of two months until the time of measurement.[9] We obtained linear measurements using 0.03-mm YATO (YT–7201) precision electronic calipers. All of the measurements were made by two independent researchers in order to reduce bias. If the differences in the results between the two researchers were greater than 10%, both of the measurements were repeated. The mean of the two measurements was calculated, with approximation to the 10th decimal place.

In all hearts, the mitral isthmus (the shortest line between the inferior margin of the LIPV ostium and the margin of the MA, perpendicular to the MA) was identified and its length was measured along their endocardial surface (ES). Then the isthmus was cut longitudinally. We divided the mitral isthmus line into three equal parts: upper 1/3 (close to the pulmonary vein ostium), middle 1/3, and lower 1/3 (close to the MA) (*Figure 1A*). The maximum thickness of myocardium was measured at each of three levels.

Then all blood vessels within the cutting line were identified and their positions were noted. The GCV and CS were cut along their free wall. The presence of the Vieussens valve and the ostium of the Marshall vein (the oblique vein of the left atrium) were both assessed. Thus we were able to locate the junction between the GCV and CS and define its relationship with the mitral isthmus line. The left coronary artery was dissected from its aortic ostium. The flexible probe was inserted into the left coronary artery and then to the LCx to identify its course. The Marshall vein was identified based on its course and the termination at the GCV/CS junction. Other blood vessels, if present, within the mitral isthmus were probed and dissected to assess their origin.

The diameters of the GCV/CS and LCx as well as the shortest distance between these two vessels were measured. Moreover, the shortest distance from the margin of the GCV/CS or LCx to the ES of the left atrium, to the venoatrial junction of the LIPV and to the MA were obtained. In the case of the LIPV absence, all the measurements were referred to the common left pulmonary vein (CLPV).[10] The medio-lateral and antero-posterior diameters of the MA were also measured.

Statistical analysis

Data are presented as the mean ± standard deviation and median with interquartile range (Q1, Q3) for continuous variables, or number (%) for categorical variables. The Shapiro–Wilk test was used to determine if the quantitative data were normally distributed. Continuous parameters were compared using the Mann–Whitney *U* test or nonparametric analysis of variance (Kruskal–Wallis) test. Wilcoxon signed-rank test with Bonferroni correction was used in pair-wise comparisons. Correlation coefficients were calculated to measure statistical dependence between heart features. The χ^2 test was used for categorical data comparison. We performed statistical analyses with STATISTICA v12 (StatSoft Inc., Tulsa, OK, USA). A *P* value of less than 0.05 was considered to be statistically significant.

Results

The mean heart weight was 435.4 ± 97.0 g and the mean length of the mitral isthmus was 28.9 ± 7.1 mm. The medio-lateral and antero-posterior diameters of the MA were 22.4 ± 6.6 and 22.2 ± 5.7 mm, respectively. The LIPV ostium was found in 90.5% and the CLPV ostium was identified in 9.5% of cases.

The mean myocardial thickness in the upper, middle, and lower 1/3 of the mitral isthmus section were 1.9 ± 1.0, 3.0 ± 1.5, and 2.7 ± 1.3 mm, respectively. Within the mitral isthmus, the left atrial myocardium is the thinnest in its upper 1/3 ($P < 0.0001$), and it is the thickest in its middle 1/3 ($P < 0.0001$) (*Figure 2*). However, in 7.5% of all hearts, we identified a significant segmental narrowing of the middle sector, where the thickness of the whole atrial wall was below 0.8 mm (*Figure 1B*).

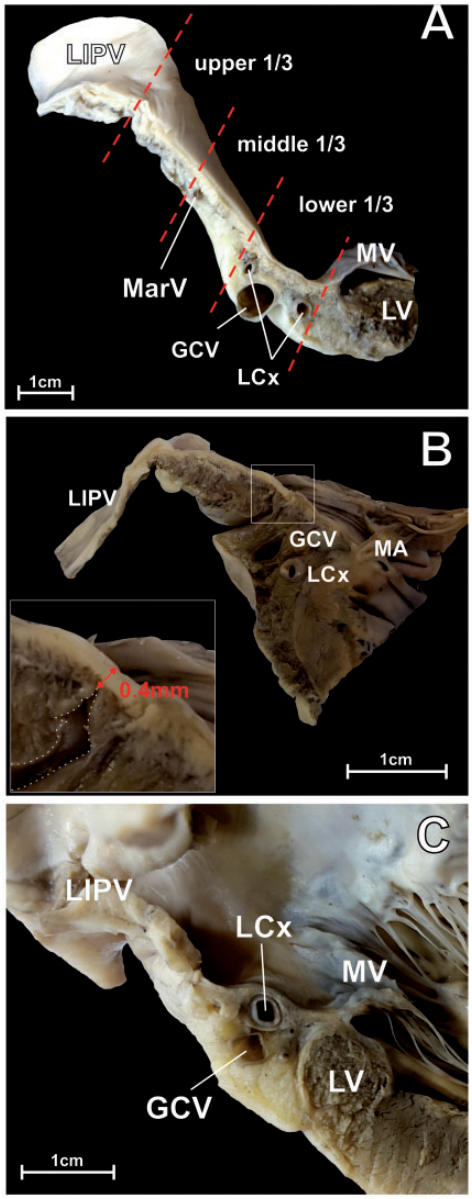

Figure 1 Photographs of a cadaveric heart specimen showing the longitudinal section through the mitral isthmus line. (*A*) The schematic division into three sectors was shown. In the middle 1/3 we can see the Marshall vein (MarV). In the lower 1/3 we found the GCV and two branches of the left circumflex coronary artery (LCx). (*B*) Segmental narrowing of left atrial wall in the middle sector of the mitral isthmus can be seen. (*C*) The LCx that is located 0.5 mm from the ES of the left atrial wall and bulges into the left atrium is visible. LV, left ventricle; MV, mitral valve.

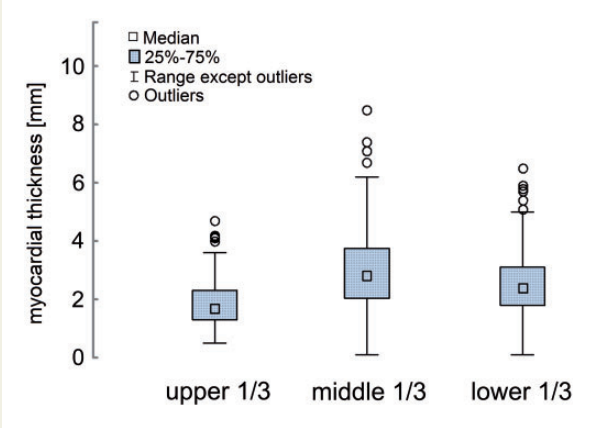

Figure 2 Box-and-Whiskers plot of median values for the myocardial thickness in different sectors of the mitral isthmus.

Among the 200 hearts, we identified the GCV in 98.0% and the CS in 1.0% of cases. The GCV was placed in the lower 1/3 of the isthmus in 78.1% (153/196) and in the middle 1/3 in 21.9% (43/196) of cases. The CS was always located in the lower 1/3 sector. The Marshall vein was found in a total of 35.0% of cases. In four cases (2.0%), an additional vein was found within the isthmus, but the Marshall vein was absent. In a further eight cases (4.0%), the additional vein accompanied the Marshall vein. Where the Marshall vein was present for 69.1% (47/68), the Marshall vein was located in the middle 1/3, and in 30.9% (21/68), it was in the upper 1/3 of the isthmus section.

The LCx was present in 57.0% of hearts (as a single branch in 98, double in 15 and 3 branches in one case). In three cases (1.5%), we found the artery that belongs to the right coronary artery tree. The arteries were located in the lower 1/3 in 55.6% (65/117) and in the middle 1/3 in 44.4% (52/117) of all hearts. Only in one heart (0.5%), there were no blood vessels within the cutting line. We were able to detect eight different patterns of GCV and LCx mutual arrangement within the mitral isthmus line, which are present in *Figure 3*.

In *Table 1*, we present the dimensions of the GCV/CS and LCx as well as their relationship to the ES of the left atrium, MA, and LIPV/CLPV venoatrial junction. The GCV diameter was correlated with the heart weight ($r = 0.20$; $P = 0.005$) and donors age ($r = 0.28$; $P = 0.00$). In 4.5% (9/198), the GCV was located closer than 2 mm from the ES and in 17.2% (34/198) closer than 3 mm. The distance between the GCV and ES was correlated with the myocardial thickness (upper 1/3: $r = 0.21$, $P = 0.003$; middle 1/3: $r = 0.20$, $P = 0.007$; lower 1/3: $r = 0.22$, $P = 0.002$). The GCV to LIPV distance was correlated with the donors age ($r = 0.24$; $P = 0.00$) and mitral isthmus length ($r = 0.36$; $P < 0.0001$). Also, when the LCx is present the GCV is significantly farther away from the ES, than when it is a single vessel in the isthmus ($P = 0.01$), but no difference is observed in the distance between the GCV and MA or LIPV ostium.

The LCx diameter increases with its distance from ES ($r = 0.20$; $P = 0.03$). On the other hand, the LCx to ES distance was correlated with the donors age ($r = 0.21$; $P = 0.02$). In 16.7% (19/114), the LCx was located closer than 2 mm from the ES and in 49.1% (56/198) closer than 3 mm (*Figure 1C*). The LCx to MA distance was also correlated with the heart weight ($r = 0.20$; $P = 0.03$). Moreover the LCx to LIPV venoatrial junction distance was correlated with the donors age ($r = 0.20$; $P = 0.04$) and mitral isthmus length ($r = 0.28$; $P = 0.002$).

There were no differences in myocardial thickness, blood vessels arrangement or their dimensions between the groups with LIPV and

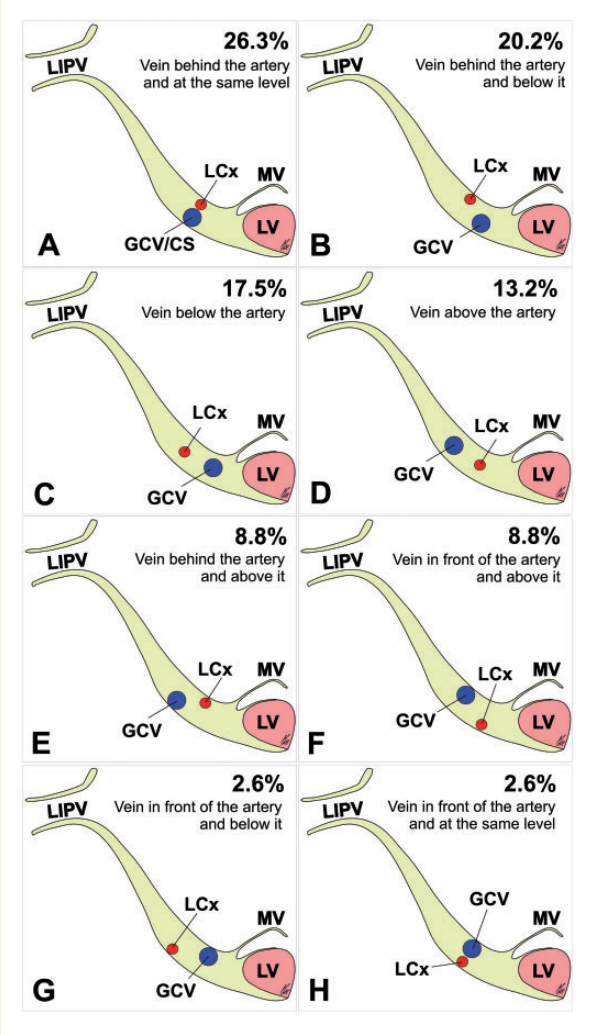

Figure 3 Schematic view of the mitral isthmus section. Eight different types of spatial relations between the GCV/CS and main branch of the LCx was presented ($N = 114$). LV, left ventricle.

CLPV. Moreover, there were no differences in the dimensions of both GCV and LCx depending on the sector in which they are located, or number of vessels within the cutting line. Also no significant differences in the myocardial thickness (on all three levels) were observed when the LCx was present or absent. There were no significant differences in any of the measured parameters between the sexes and no other significant correlations with donor's weight, body mass index, or body surface area.

Discussion

This study described the anatomy of the longitudinal section of the mitral isthmus line, which is of great interest to invasive electrocardiologists. First, we measured the myocardial thickness of the left atrium within the isthmus, which was the thinnest on the pulmonary vein end of the mitral isthmus. The remaining sectors of the mitral isthmus (middle and lower) are significantly thicker. Our results are contrary to the findings of Becker. Based on 20 heart specimens, he found that the mitral isthmus myocardium is the thickest at the level of the orifice of the pulmonary vein (3.2 ± 1.5 mm).[5] However, our results conform with those of Wittkampf *et al.*[6] where the atrial wall was the thickest midway, with tapering at either end of the isthmus. In computed tomography-based study by Cho *et al.*,[11] the myocardium was the thickest near the pulmonary vein end of the mitral isthmus line both in patients with atrial fibrillation (2.3 ± 0.9 mm) and in sinus rhythm (2.5 ± 0.7 mm), which goes against our results. The knowledge of the tissue thickness is clinically useful, since isthmus thickness predicts ablation failure.[12]

One of our findings requires special attention. In 7.5% of all hearts, we identified the significant segmental narrowing of the middle sector, where the thickness of the whole atrial wall was extremely thin and the myocardium was composed of only a few fibers. However, there were no such cases in previous anatomical studies, but these were analyzing a much smaller group of hearts.[5,6] The segmental narrowing of the middle sector reported in this study and crevices (or pouches, recesses) described by other authors are not the same observations.[4,6,13] In contrast to crevices, the segmental narrowing in the middle sector could not be observed form the ES. In all hearts where the narrowing was observed, the endocardium was smooth at the level of this anomaly (*Figure 1B*). It seems that this reduction in the left atrial wall thickness is the result of impaired arrangement of the superficial layer of muscular fibers of the left atrium.[14] This place seems to be particularly dangerous; both the delivery of even a low radiofrequency energy and mechanical trauma may lead to perforation and cardiac tamponade. Cardiac tamponade is the most common complication in atrial fibrillation ablation and may occur in up to 2.8–5.0% of patients undergoing mitral isthmus ablation.[15,16] It was also found that the risk of tamponade is higher in this procedure than in the cavotricuspid isthmus ablation or pulmonary vein isolation.[16] We advise ablation practitioners to limit the power within this area (middle sector) to the lowest level which is necessary to achieve mitral isthmus block.[2] It can be useful to evaluate mitral isthmus anatomy before mitral isthmus ablation and, if possible, avoid this procedure in patients with extremely thin left atrial wall.

The presence of the blood vessels inside the isthmus greatly influences the likelihood of achieving the complete block and is responsible for many complications. The knowledge of its most common anatomical variants and pre-ablation vessels imaging may help to plane the procedure and increase its safety and efficiency.[17] We found that the GCV is the most common blood vessel within the mitral isthmus section, which could be found in almost all cases with a mean diameter of 4.1 ± 1.2 mm. We want to draw attention to the proper nomenclature; as almost all authors and clinicians named the venous vessel inside the isthmus as the CS. However, it is not the CS but the GCV that is present within the isthmus, thus we should avoid this common error. The GCV diameter increases with age and heart weight. It was proven that the GCV is responsible for the heat sink effect that is one of the obstacles to successful mitral isthmus ablation.[18] Wong *et al.* based on group of 35 patients found that a larger venous diameter was significantly associated with the need for epicardial delivery of radiofrequency energy through the GCV, the total mitral isthmus ablation time and GCV ablation time. He also concluded, that venous diameter > 5.9 mm predicted the need for epicardial

Table 1 Dimensions of the main blood vessels identified within the mitral isthmus line and their relations to the ES, MA, and venoatrial junction of the left inferior (or common left) pulmonary vein

	N	Mean	SD	Min	Max	Median	Q_1	Q_3
GCV/CS diameter (mm)	198	4.1	1.2	1.4	9.3	4.0	3.2	4.9
GCV/CS to LA ES distance (mm)	198	4.5	2.2	1.0	23.7	4.1	3.2	5.5
GCV/CS to LIPV/CLPV venoatrial junction distance (mm)	198	24.3	7.3	7.2	44.2	23.6	19.4	29.4
GCV/CS to MA distance (mm)	198	7.3	5.3	0.1	40.1	6.3	4.1	9.1
GCV to LCx distance (mm)	114	2.4	2.3	0.1	17.5	1.9	1.1	3.2
LCx diameter (mm)	114	2.3	1.0	0.4	7.3	2.2	1.6	2.8
LCx to LA ES distance (mm)	114	3.8	2.3	0.2	11.8	3.0	2.3	5.1
LCx to LIPV/CLPV venoatrial junction distance (mm)	114	25.3	8.0	7.2	46.0	24.6	20.0	31.0
LCx to MA distance (mm)	114	7.9	5.1	0.1	28.6	7.0	4.5	9.9

N, number of samples; Q_1 and Q_3, lower and upper quartiles; LA, left atrium.

ablation (specificity: 100%; sensitivity: 78%).[19] In our study, the GCV diameter in the mitral isthmus area was >5.9 mm in 7.5% (15/200) of all cases. However, clinically the epicardial ablation is necessary in majority of patients. Taking this into account, we should ask whether a cut-off GCV diameter that may predict the need for epicardial ablation should be changed? Especially that it has been developed based on a small group of patients, and this value may not be adequate. We also consider that not only the diameter, but also the location of the GCV and its relation to LCx or ES may influence the ablation. The heat sink effect caused by the GCV/CS located sub-endocardially (23.5% of hearts) may be greater than that from the vein located at a distance from the endocardium. Thus, the epicardial ablation may be necessary not only when the GCV diameter is large but also when the vein is located closer to the ES.

The LCx is much less frequently encountered vessel in this area (57.0%). Right coronary artery branches are rarely found in mitral isthmus. It seems that the presence of the LCx is less responsible for removing the heat from the ablation site than the GCV.[19] However, serious complications, such as artery injury and acute occlusion, may result from their location inside the isthmus. Fortunately, the LCx is absent within the mitral isthmus section in 20.0–43.0%, and in those patients, the ablation is consequently much safer.[20] In the remaining cases, the artery may be thermally injured by radiofrequency energy delivered both from ES and within the GCV/CS.[7,21] The LCx is located at a shorter distance from the ES than the GCV (3.8 ± 2.3 vs. 4.5 ± 2.2 mm) and is located closer than 3 mm from ES in 49.1% (56/198). The GCV and LCx usually run in close proximity to each other (mean distance 2 mm), often separated by a very thin layer of fat tissue. The mutual relationship between the GCV and LCx seems to be crucial (*Figure 3*). It was proven that LCx interposed between the GCV and mitral isthmus is a predictor of unsuccessful linear ablation during endocardial and epicardial ablation.[17] We found that such an undesirable arrangement of vessels, where the GCV is located just behind the artery, is the most common anatomical variant (26.3%, *Figure 3A*). In those patients an injury to the artery is almost certain when performing the epicardial ablation from the coronary venous system. Moreover, in 29.0% of cases the LCx is located between the GCV and ES of the left atrium, but at a greater vertical distance (*Figure 3B and E*). We found that the LCx diameter increases with the distance between the artery and endocardium. The LCx located sub-endocranially is smaller in diameter and therefore may be more vulnerable to thermal injury.

In our study, we analysed the positions of blood vessels depending on their distance from the LIPV and MA. The Marshall vein is the only vessel we should expect in the upper isthmus sector. More blood vessels may be found closer to the annular end of the isthmus. It may explain why most reconnections occur at the annular end of the ablation line.[2] Our results confirmed that both the GCV and LCx are not located just at the level of the MA but run about 6–8 mm above it and thus cannot be used as a markers for MA location.[5] Moreover, the distance between the LIPV ostium and the GCV or LCx may be clinically important, especially for the safety of the radiofrequency catheter pulmonary vein isolation. In this study, the minimal distance between the LCx and the venoatrial junction of the LIPV was 7.2 mm. The same minimal distance was observed for the GCV. Majority of the mitral isthmus dimensions, including the distance between the LCx/GCV and venoatrial junction of the LIPV, show a positive correlation with donors age.

The elegant study of Randhawa *et al.* also investigated the spatial relationship of blood vessels at the level of mitral isthmus, based on 50 non-dilated cardiomyopathy and 20 dilated cardiomyopathy cadaveric heart specimens. In that study, the mean diameter of GCV/CS was found to be 2.64 ± 0.66 mm in normal hearts, which is almost two times smaller than in our study (4.1 ± 1.2 mm). It was also shown that the GCV/CS was located above the MA (4.18 ± 2.91 mm vertically and 2.60 ± 1.35 mm horizontally). In non-dilated cardiomyopathy hearts, the LCx was located below the GCV/CS in 36% of cases; in 20% it was interposed between the GCV/CS and endocardium; and in 12% above the GCV/CS and in 4% between the GCV/CS and epicardial surface. There are visible differences in observed arrangement of blood vessels within the isthmus compared to current study, which may result from a relatively small study group analyzed by Randhawa *et al.*[20]

This study has several limitations. First, all the measurements were made on autopsied heart specimens after formaldehyde fixation, which may result in slight changes in size and shape of the heart. However, the use of 10% paraformaldehyde does not cause significant changes in the dimensions of the atrial tissue. The dimensions of

fixed hearts are similar to those before fixation.[9] It was also found that the diameters of blood vessels do not change significantly during 10% paraformaldehyde fixation.[9] However, we cannot conclude anything about the behavior and dimension changes of the studied area within the cardiac cycle, including the dimensions of studied blood vessels. Second, no histological sections were made, which may most affect the accuracy of the myocardial thickness measurement. Third, we have measured only the myocardial thickness, not the whole atrial wall thickness. We have chosen this measurement approach, because the myocardium plays crucial role in mitral isthmus ablation and information about its thickness is clinically useful. The presence of irregular layer of epicardial fat which vary considerably between individuals makes the measurement of the whole atrial wall thickness clinically irrelevant. Fourth, all hearts were dissected not from patients with atrial fibrillation and therefore represent only the normal anatomy of the studied region. Despite these limitations, we believe that they do not impede the morphological analysis of relationships between individual heart structures and their relative dimensions within the mitral isthmus line.

Conclusion

The myocardium of the mitral isthmus line is thinnest in its upper 1/3 sector and the main blood vessels are mainly located in the middle and lower 1/3. In 7.5% of all hearts, the significant segmental narrowing of the middle sector (below 0.8 mm) may be found.

The mitral isthmus line transects the GCV in 98.0%, the LCx in 57.0%, and the Marshall vein in 35.0% of all hearts. The LCx (if present) is located between the GCV/CS and ES of the left atrium in 55.3% of cases. In almost half of the cases, the LCx is situated at a distance of less than 3 mm from the ES. Both the veins and arteries within the mitral isthmus are located significantly above the MA. Evaluation of the mitral isthmus anatomy before mitral isthmus ablation can be useful. The knowledge of its most common anatomical variants and pre-ablation vessels imaging may help to plane the procedure and increase its safety and efficiency.

Conflict of interest: none declared.

References

1. Luria DM, Nemec J, Etheridge SP, Compton SJ, Klein RC, Chugh SS *et al*. Intra-atrial conduction block along the mitral valve annulus during accessory pathway ablation: evidence for a left atrial "isthmus". *J Cardiovasc Electrophysiol* 2001;**12**:744–9.
2. Wong KC, Betts TR. A review of mitral isthmus ablation. *Indian Pacing Electrophysiol J* 2012;**12**:152–70.
3. Matsuo S, Wright M, Knecht S, Nault I, Lellouche N, Lim KT *et al*. Peri-mitral atrial flutter in patients with atrial fibrillation ablation. *Heart Rhythm* 2010;**7**:2–8.
4. Cabrera JA, Pizarro G, Sánchez-Quintana D. Muscular architecture of the mitral isthmus: anatomical determinants for catheter ablation. *Europace* 2012;**14**:1069–71.
5. Becker AE. Left atrial isthmus: anatomic aspects relevant for linear catheter ablation procedures in humans. *J Cardiovasc Electrophysiol* 2004;**15**:809–12.
6. Wittkampf FH, van Oosterhout MF, Loh P, Derksen R, Vonken EJ, Slootweg PJ *et al*. Where to draw the mitral isthmus line in catheter ablation of atrial fibrillation: histological analysis. *Eur Heart J* 2005;**26**:689–95.
7. Takahashi Y, Jaïs P, Hocini M, Sanders P, Rotter M, Rostock T *et al*. Acute occlusion of the left circumflex coronary artery during mitral isthmus linear ablation. *J Cardiovasc Electrophysiol* 2005;**16**:1104–7.
8. Nakamura T, Aoyagi H, Yamauchi Y, Okishige K. Coronary sinus stenosis as collateral damage of radiofrequency ablation in patients with atrial fibrillation. *JACC Clin Electrophysiol* 2016;**2**:759–61.
9. Hołda M, Klimek-Piotrowska W, Koziej M, Piątek K, Hołda J. Influence of different fixation protocols on the preservation and dimensions of cardiac tissue. *J Anat* 2016;**229**:334–40.
10. Klimek-Piotrowska W, Hołda MK, Piątek K, Koziej M, Hołda J. Normal distal pulmonary vein anatomy. *PeerJ* 2016;**4**:e1579.
11. Cho Y, Lee W, Park EA, Oh IY, Choi EK, Seo JW *et al*. The anatomical characteristics of three different endocardial lines in the left atrium: evaluation by computed tomography prior to mitral isthmus block attempt. *Europace* 2012;**14**:1104–11.
12. Latcu DG, Squara F, Massaad Y, Bun SS, Saoudi N, Marchlinski FE. Electroanatomic characteristics of the mitral isthmus associated with successful mitral isthmus ablation. *Europace* 2016;**18**:274–80.
13. Cabrera JA, Ho SY, Climent V, Sánchez-Quintana D. The architecture of the left lateral atrial wall: a particular anatomic region with implications for ablation of atrial fibrillation. *Eur Heart J* 2008;**29**:356–62.
14. Ho SY, Anderson RH, Sánchez-Quintana D. Atrial structure and fibres: morphologic bases of atrial conduction. *Cardiovasc Res* 2002;**54**:325–36.
15. Jaïs P, Hocini M, Hsu LF, Sanders P, Scavee C, Weerasooriya R *et al*. Technique and results of linear ablation at the mitral isthmus. *Circulation* 2004;**110**:2996–3002.
16. Hsu LF, Jaïs P, Hocini M, Sanders P, Scavée C, Sacher F *et al*. Incidence and prevention of cardiac tamponade complicating ablation for atrial fibrillation. *Pacing Clin Electrophysiol* 2005;**28** Suppl 1:S106–9.
17. Yokokawa M, Sundaram B, Garg A, Stojanovska J, Oral H, Morady F *et al*. Impact of mitral isthmus anatomy on the likelihood of achieving linear block in patients undergoing catheter ablation of persistent atrial fibrillation. *Heart Rhythm* 2011;**8**:1404–10.
18. Wong KC, Jones M, Qureshi N, Sadarmin PP, De Bono J, Rajappan K *et al*. Balloon occlusion of the distal coronary sinus facilitates mitral isthmus ablation. *Heart Rhythm* 2011;**8**:833–9.
19. Wong KC, Jones M, Sadarmin PP, De Bono J, Qureshi N, Rajappan K *et al*. Larger coronary sinus diameter predicts the need for epicardial delivery during mitral isthmus ablation. *Europace* 2011;**13**:555–61.
20. Randhawa A, Saini A, Aggarwal A, Saikia UN, Tubbs RS, Gupta T *et al*. Spatial relationship of coronary sinus-great cardiac vein to mitral valve annulus and left circumflex coronary artery: implications for cardiovascular interventional procedures. *Cardiovasc Pathol* 2016;**25**:375–80.
21. Wong KC, Lim C, Sadarmin PP, Jones M, Qureshi N, De Bono J *et al*. High incidence of acute sub-clinical circumflex artery 'injury' following mitral isthmus ablation. *Eur Heart J* 2011;**32**:1881–90.